

Accidental Barbie Doll–Related Vaginal Laceration in a 7-Year-Old

Paige Condit MD

University of Wisconsin School of Medicine and Public Health

Jennifer Schramm MD

Children's National Health System

Debra Esernio-Jenssen MD

Lehigh Valley Health Network, debra.esernio-jenssen@lvhn.org

Dobie L. Giles MD

University of Wisconsin School of Medicine and Public Health

Barbara L. Knox MD

University of Wisconsin School of Medicine and Public Health

Follow this and additional works at: <https://scholarlyworks.lvhn.org/emergency-medicine>



Part of the [Emergency Medicine Commons](#), [Obstetrics and Gynecology Commons](#), and the [Pediatrics Commons](#)

Let us know how access to this document benefits you

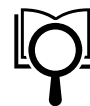Published In/Presented At

Condit P, Schramm J, Esernio-Jenssen D, Giles DL, Knox BL. (2020). Accidental Barbie doll–related vaginal laceration in a 7-year-old. *Consultant*, 60(2), 54-57. doi:10.25270/con.2020.02.00005

This Article is brought to you for free and open access by LVHN Scholarly Works. It has been accepted for inclusion in LVHN Scholarly Works by an authorized administrator. For more information, please contact LibraryServices@lvhn.org.

Foreign-Body Ingestion
Resource Center

PHOTOCLINIC



Accidental Barbie Doll–Related Vaginal Laceration in a 7-Year-Old

Volume 60 - Issue 2 - February 2020



AUTHORS:

Paige Condit, MD

Department of Pediatrics, University of Wisconsin School of Medicine and Public Health, Madison, Wi

Jennifer Schramm, MD

Department of Pediatric Cardiology, Children’s National Health System, Washington, DC

Debra Esernio-Jenssen, MD

Department of Pediatrics, Lehigh Valley Health Network, Allentown, Pennsylvania

Dobie L. Giles, MD

Department of Obstetrics and Gynecology, University of Wisconsin School of Medicine and Public He.

Barbara L. Knox, MD

Department of Pediatrics, University of Wisconsin School of Medicine and Public Health, Madison, Wi

CITATION:

Condit P, Schramm J, Esernio-Jenssen D, Giles DL, Knox BL. Accidental Barbie doll–related vaginal laceration in a 7-year-old. Consultant. 2020;60(2):54-57. doi:10.25270/cons.2020.02.000005

migraine360 primary care dinner series

Connect With The Experts.
Plus... Dinner and Drinks On Us!


Foreign-Body Ingestion Resource Center

History. The child disclosed to the child abuse pediatrician that she had been playing in the bathtub with several Barbie dolls while showering. As she had attempted to exit the tub, her foot had slipped on and fall onto the raised leg of another doll (**Figure 1**). The child further stated that the leg of the doll was pushed into her and that it did “go into my body.” She stated that as a result, she screamed in pain.




Figure 1. The scene of the bathtub and Barbie dolls as recreated by the child. Note that one doll has its leg pointed upward during impalement.

The child was able to correctly identify the parts of her body that are considered “private.” She did not touch her private parts or having touched her in a manner that made her feel uncomfortable. The child



migraine360 primary care dinner series

Connect With The Experts.
Plus... Dinner and Drinks On Us!


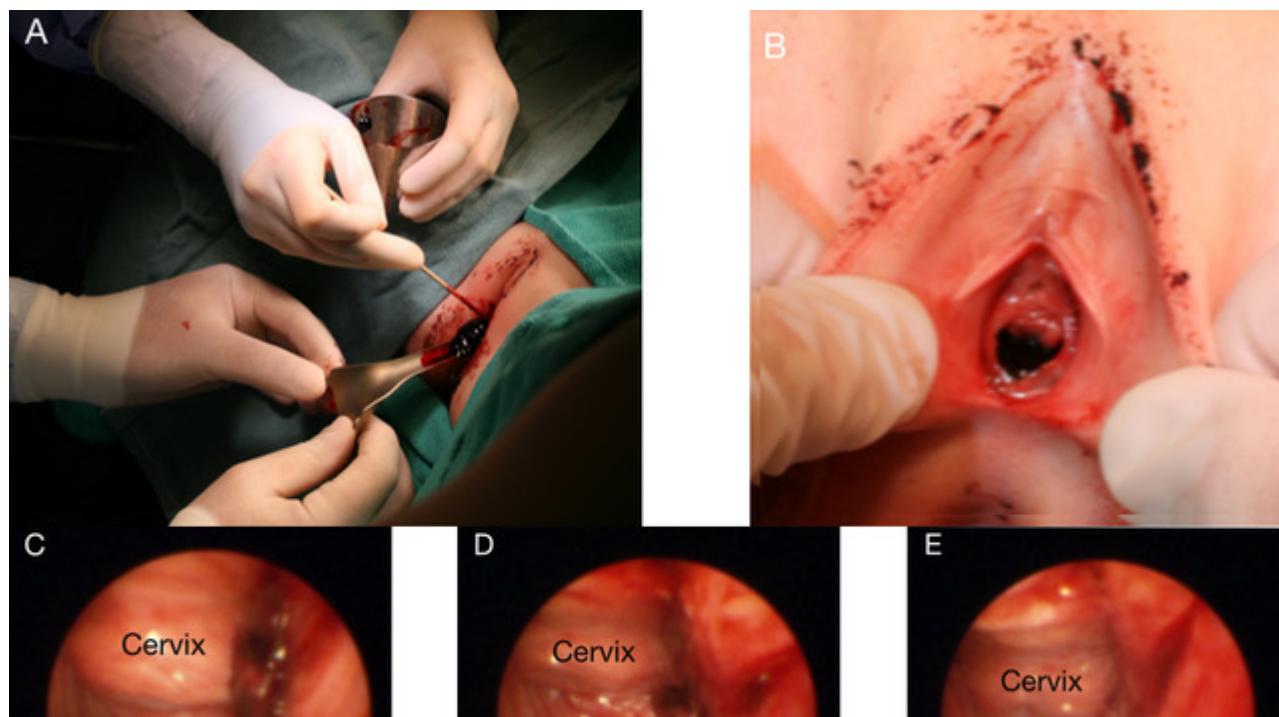


Foreign-Body Ingestion Resource Center

The child was the product of a full-term twin pregnancy with cesarian delivery. Her medical history was significant for autoimmune polyendocrine syndrome type 1 and common variable immune deficiency. Both disorders had been well controlled with standard treatment at home with her biologic parents, her twin sister, an older sister (age 10) and 2 foster children (ages 2 and 4). There were no prior concerns for abuse or neglect.

Physical examination. The child abuse pediatrician found no bruising of the child’s hymen and no trauma to the vulva. Large clots of blood were present in the vaginal vault. The rugal folds were normal without fissures, and the cervix was normal. The remainder of the physical examination findings were normal. The child was admitted for examination under anesthesia for removal of the clots.

EUA reaffirmed the lack of injury to the labia, hymen, and posterior fourchette. (Figures 2A and 2B). Large clots were noted on vaginoscopic examination and were subsequently removed. The examination also revealed a vaginal sidewall laceration in the upper third of the vagina, to which a hemostatic agent was applied. The child tolerated the procedure well and was discharged home on postoperative day 1.



Connect With The Experts.
Plus... Dinner and Drinks On Us!



Foreign-Body Ingestion Resource Center

Diagnosis. The child abuse pediatrician diagnosed this case as being consistent with the accidental r child’s corroborated history and physical findings were attributable to a vaginal laceration due to impal doll.

HMP Global

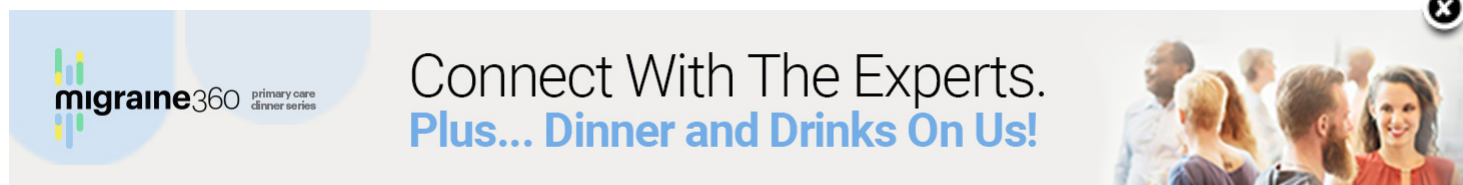
HMP Education

HMP Omnimedia

HMP Europe

© 2022 HMP Global. All Rights Reserved.

[Privacy Policy](#) [Terms of Use](#)



migraine360 primary care dinner series

Connect With The Experts.
Plus... Dinner and Drinks On Us!